



# Indian Internet Journal of Forensic Medicine and Toxicology

Vol. 18, No. 2, April-June 2020

<b>Editorial Board</b>	<b>Contents</b>	<b>Page No.</b>
<b>Founder</b> <b>Prof. Dogra TD</b>	<i>Original Articles</i>	
<b>Editor</b> <b>Dr. Mukesh Yadav</b>	<i>Postmortem Evaluation of Autolytic Changes in Morphology of Red Blood Cells and Haemogram Pattern for Estimation of Time since Death</i> <i>Ashish Tyagi, Shilpa Garg and Hitesh Chawla</i>	23
<b>Assistant Editors</b> <b>Dr. Lalwani S</b> <b>Dr. Srivastav PC</b>	<i>A Statistical Study of Gender Differentials and Patterns in Suicidal Deaths</i> <i>Mahesh Chand Meena, Sunil Naagar, Pratibha Meena, Kulbir and Mukesh Kumar Bansal</i>	29
<b>Members</b> <b>Prof. Javed Usmani</b> <b>Prof. PC Dikshit</b> <b>Prof. SK Verma</b> <b>Prof. Dalbir Singh</b> <b>Prof. Atul Murari</b> <b>Prof. RK Gorea</b> <b>Prof. Ashok Srivastav</b> <b>Prof. Nagesh G Rao</b> <b>Prof. NK Agarwal</b> <b>Prof. OP Murty</b> <b>Prof. Gautum Biswas</b>	<i>AIIMS Follow up on Medical Ethics; RTI Act Provided Rescue</i> <i>Vaibhav Jain, Mukesh Yadav and Mukesh Kumar Bansal</i>	37
	<i>Gender Differentiation by Articulated Pelvic Index: A Radiological Study Over the Population of Bihar</i> <i>Gautam Kumar, Avinash Kumar, Amit Patil, Binay Kumar, Ashok Kumar Rastogi and Nawal Kumar Singh</i>	41

ICFMT, its editor and publisher disclaim responsibility and liability for any statement of fact and opinion, originality of contents and of any copyright violations by the author.

**Printed & Published by:** Diva Enterprises Pvt. Ltd. on behalf of Indian Congress of Forensic Medicine and Toxicology **Printed at** Spectrum, 208 A/14A, Savitri Nagar, New Delhi 110 017, **Published at** Diva Enterprises Pvt. Ltd., B-9, A-Block, L.S.C., Naraina Vihar, New Delhi 110028, India, **Editor** Dr. Mukesh Yadav



**Original Article**

## Gender Differentiation by Articulated Pelvic Index: A Radiological Study Over the Population of Bihar

Gautam Kumar<sup>1</sup>, Avinash Kumar<sup>2\*</sup>, Amit Patil<sup>3</sup>, Binay Kumar<sup>4</sup>, Ashok Kumar Rastogi<sup>5</sup> and Nawal Kumar Singh<sup>6</sup>

<sup>1</sup>Assistant Professor, Department of Forensic Medicine & Toxicology, Dumka Medical College & Hospital, Dumka, Jharkhand, India

<sup>2</sup>Senior Resident, <sup>3</sup>Additional Professor and Head of Department, <sup>4</sup>Additional Professor, <sup>5</sup>Assistant Professor, <sup>6</sup>Senior Resident, Department of Forensic Medicine & Toxicology, All India Institute of Medical Sciences, Patna, Bihar, India

\*Corresponding author email id: staravinash008@gmail.com

Received: 18-08-2020; Accepted: 31-08-2020

### ABSTRACT

**Introduction:** Identification is the establishment of the identity of a person with the help of different physical characteristics. The different physical characteristics of the human skeleton between both the genders is the reason for Sexual dimorphism. Many researchers have studied and observed the different parameters for sexual dimorphism in different bones. Pelvis is the most important bone for determination of gender because the sexual dimorphism is present even in the fetal stage. In the modern era of advancement, pathological autopsy is shifting towards the virtual autopsy in which CT scan, MRI and X-rays are replacing the conventional autopsy instruments. **Aims and Objective:** To establish gender differentiation criteria in the population of Bihar based on Articulated Pelvic index. **Methodology:** we used 200 antero-posterior views of pelvic digital radiograph, equal from both genders. Through digital radiograph of pelvis we measured maximum length of pelvic bone between summit of iliac crest to ischial tuberosity and maximum width of pelvic bone between two anterior superior iliac spine with DICOM software and calculated articulated pelvic index. **Observation and Results:** Articulated pelvic index of pelvis in male and female gender is 133.96 with SD 11.47 and 133.96 with SD 11.47 respectively. **Conclusion:** females had significantly higher mean value of articulated pelvic index than males.

**Keywords:** Anterior superior iliac spine, Articulated pelvic index, Iliac crest, Ischial tuberosity, Pubis, Sexual dimorphism

### INTRODUCTION

Identification is establishment of individuality of a person based on certain physical characteristics, and its establishment is an essential in civil cases and as a component of corpus delicti in criminal cases<sup>[1]</sup>. Among all identification data, gender is one of the most important

components. Gender can be determined by external genitalia, internal sexual organs, sex chromatin and by the gross examination of skeleton/Osteology<sup>[2]</sup>. Osteological determination of gender is a routine practice in Forensic Medicine and Toxicology. Gender identification is easier when a person is alive or if the corpse is not mutilated or not in an advanced stage of

decomposition. In a mutilated and highly decomposed body due to absence of external and internal sexual organs, gender identification becomes difficult. In these situations, osteometry becomes very useful for gender differentiation. Osteometric measurement is done in the living or during postmortem examination. During postmortem bones can be extracted and measurement can be taken by osteometric board. Through radiological means osteometric measurements can be taken both in the living and the dead, without cumbersome process of extraction. So, radiology can contribute to gender determination by providing precise dimensions both in living as well as in the dead [3].

In osteometry, various bones are taken in consideration for sexual differentiation but among them pelvis alone is best to differentiate gender among all other bones. Due to evolution and birth capacity, the female pelvis shows sexual dimorphism. The renowned anthropologist “William Krogman’s” study says pelvis shows sexual dimorphism since birth and it can predict gender up to 95% accuracy [4]. These are subpubic angle, ischio-pubic index, pubic angle 1 and pubic angle 2, “X” angle, ratio between minimum width of pubic body to pubic symphysis, ratio of midwidth of pubic body to pubic symphysis etc. [5].

In conventional methods, these measurements can be taken from osteometric boards, calipers and measuring scales. In the era of the recent advances in medical sciences, such measurements can be assessed through digital x-ray with DICOM software.

In our study, we are validating the various known measurements and indices to differentiate male or female gender and also introducing a new index i.e. articulated pelvic index [(maximum breadth of pelvis x 100)/maximum length of pelvis] for gender identification.

## **AIMS AND OBJECTIVES**

To establish gender differentiation criteria in the population of Bihar based on the Articulated Pelvic index.

## **TYPE OF RESEARCH STUDY**

Hospital record based descriptive study.

## **METHODOLOGY**

**Sample size:** A total of 200 digital radiographs equally from both the genders. All the pelvic anterior-posterior views of digital radiography were taken from the hospital record of AIIMS Patna.

### **Inclusion criteria**

1. The patient who visited Radiology Department of AIIMS Patna for Pelvic X-ray examination as a part of their treatment.
2. The sex of the patient is properly documented on the x-ray film.
3. The patient of any age.

### **Exclusion criteria**

1. X-ray of fracture pelvis.
2. Patient having any genetic pelvic deformity visible on x-ray.
3. Pregnant patient.
4. Overexposed or underexposed and rotated x-ray photograph.

On approval from the institutional research committee, a descriptive research study started on 200 study samples. Digital radiographs from 200 study samples were taken equally from each gender. These radiographs taken were from the hospital records of those patients who visited the department of radiology during the course of treatment and were advised for anterior-posterior view of pelvic x-ray. The digital x-rays of the patients which fulfilled both the inclusion and exclusion criteria were taken into consideration for the study. The softcopy of digital x ray was studied with the help of DICOM software. Through DICOM software, the following measurements of pubic angles were taken.

**Articulated Pelvic index:** The technique used for measuring the maximum length of pelvic bone between summit of iliac crest to ischial tuberosity to maximum width of pelvic bone between two anterior superior iliac spine by anterior superior iliac spines.

All data thus collected were entered in excel sheet and statistical analysis were done through excel and SPSS. Means of above variables and unpaired t-test were calculated.

### MATERIAL AND METHODS

**Materials included:** Computer, PACS (picture archiving and communication system), Digital X-ray machine, digital x-ray (antero-posterior view of pelvis), DICOM software, SPSS software, Microsoft excel software and calculator.

**Measurement Technique:** The measurement of the distance between the points of interest (as shown in (Figure 1 & 2) were taken from DICOM file (the

softcopy of digital x ray) through DICOM software e.g. RadiAnt DICOM viewer. In the tool bar of RadiAnt DICOM viewer, angle for the measurement of corresponding physical property were chosen and angle measurements were taken.

### Observations and Results

Articulated pelvic index of pelvis in male and female gender is 133.96 with SD 11.47 and 133.96 with SD 11.47 respectively. Articulated pelvic index of pelvis for determination of gender is statistically insignificant as depicted below.

For Articulated pelvic index the area under ROC curve is 81.8% (95% CI 75.9%-87.6%,  $p < 0.0001$ ) for sex differentiation is seen in graph 1. Articulated pelvic index is different in male and female and is higher in female. In the study population, applying a differentiation point of 139.31 the sensitivity of 72%, specificity of 75% for female gender. In studied population of Bihar a significant difference is noted in the average size of articulated pelvic

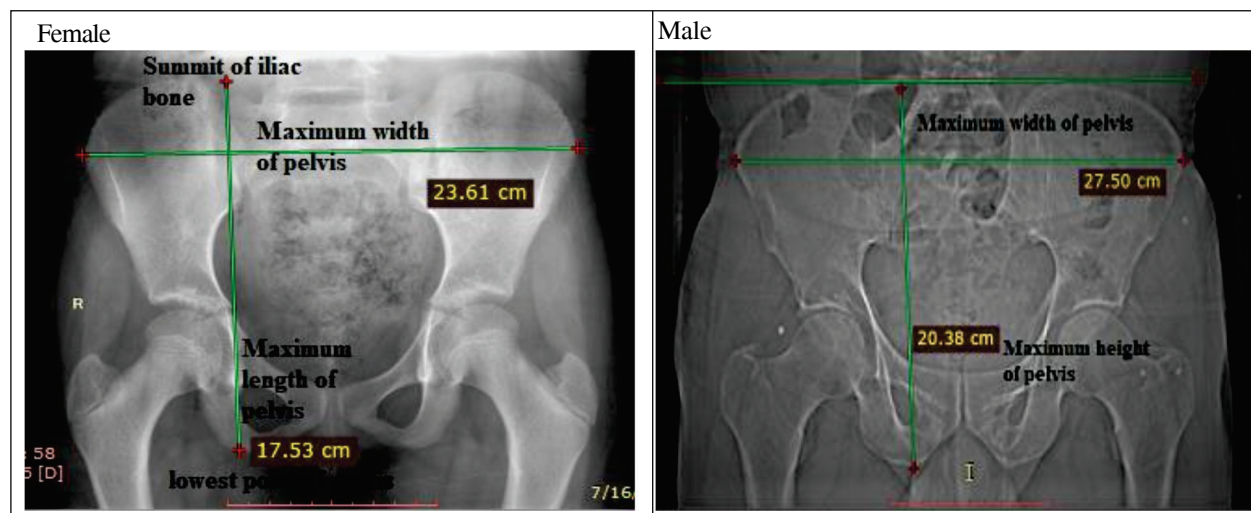
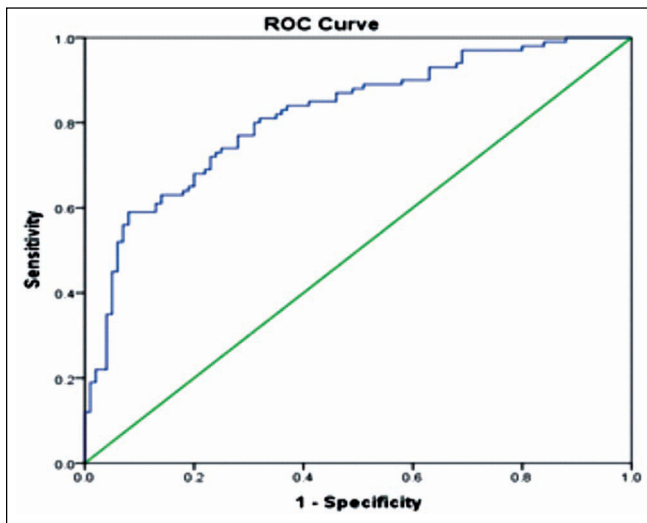


Figure 1 and 2: Length of pubis & Length of Ischium

Articulated pelvic index = maximum width of articulated pelvis/maximum length of articulated pelvis x 100	Mean	Standard deviation	Unpaired t test
Female	145.91	9.16	P value < 0.0001; t = 8.1478; df = 198; std error of difference = 1.468
Male	133.96	11.47	

Comparison of articulated pelvic index means between male and female gender.



**Graph 1: Showing Area Under ROC Curve in Articulated Pelvic Index**

index between men and woman, with average size is significantly less than female that in men ( $p < 0.0001$ ).

## DISCUSSION

A total of 200 digital x-ray of pelvis, including both the gender in equal proportion from population of Bihar was taken for study. In anterior-posterior view of pelvic digital x-ray articulated pelvic index were calculated and observed. Population ages from 3 month to 85 year were selected for our study. Length and width were not considered as a variables for differentiating gender in population, but the index/ ratio derived from these variables were used for determination of gender. So, Articulated pelvic index can be used for determination of gender.

In our study we developed an easy test for gender determination. Because (As) male pelvis is long and slender but female pelvis is broader and stouter<sup>[7]</sup>. So, when we divide length of maximum breadth of pelvis to maximum length of pelvis we will get different result for male and female. So, a new index is formed by dividing the maximum breadth of pelvis to maximum length of pelvis and then multiplied by 100. We named it Articulated pelvic index. We found a statistically significant ( $p$  value  $< 0.0001$ ) value of articulated pelvic index for gender

determination. We found higher value of articulated pelvic index in female than in male. In female the mean of articulated pelvic index is  $145.91 \pm 9.16$  and in male  $133.96 \pm 11.47$ . The new index was authenticated and validated by 30 new additional data. These new data were taken by third party to avoid investigator bias. With the help of our result we correctly determine gender in 26 cases, but in 4 cases this result failed to diagnose gender correctly. So, in authentication and validation of Articulated pelvis index we correctly diagnosed the gender in 86.66% cases.

## CONCLUSION

In our study we used digital radiograph of pelvic bone for determination of gender. Through digital radiograph of pelvis we measured the maximum length of pelvic bone between summit of iliac crest and ischial tuberosity to maximum width of pelvic bone between two anterior superior iliac spine by anterior superior iliac spines length of pubis and calculated Articulated pelvis index. We observed that females had significantly higher mean value than males.

**Approval from IRC:** Approved from IRC AIIMS, Patna

**Acknowledgement:** Department of Radio-diagnosis, AIIMS, Patna

**Conflict of Interest:** None

**Financial Support:** Nil

## REFERENCES

- [1] Reddy KSN. The essentials of Forensic Medicine and Toxicology. 34<sup>th</sup> ed. New Delhi: Jaypee Brothers Medical Publishers. 2017.
- [2] Di Vella G, Campobasso CP, Dragone M, Introna F. Skeletal sex determination by scapular measurements. *Bollettino-Societa Italiana Di Biologia Sperimentale*. 1994;70(2):299–310.
- [3] Krogman WM, Iscan MY. The human skeleton in forensic medicine, Charles C. Thomas, Springfield, IL. 1986;15(2):202-08.

- [4] Memarian A, Aghakhani K, Mehrpisheh S and Fares F. Gender determination from diagnostic factors on anteroposterior pelvic radiographs. *Journal of the Chinese Medical Association*. 2017;80(2):155-175. doi:10.1016/j.jcma.2016.06.009.
- [5] Karmakar RN. *Forensic medicine and toxicology*. Academic Publishers; New Delhi, 2010.

**How to cite this article:** Gautam Kumar, Avinash Kumar, Amit Patil, Binay Kumar, Ashok Kumar Rastogi and Nawal Kumar Singh. Gender Differentiation by Articulated Pelvic Index: A Radiological Study Over the Population of Bihar. *Indian Internet Journal of Forensic Medicine & Toxicology*. 2020;18(2):41-45.